

## Research Article

# Adenoid Cystic Carcinoma; A Single Center 15 Years Experience and Literature Review

 Celal Alandag,<sup>1</sup>  Seher Nazli Kazaz,<sup>2</sup>  Bengu Cobanoglu<sup>3</sup>

<sup>1</sup>Department of Medical Oncology, Sivas Numune Hospital, Sivas, Turkey

<sup>2</sup>Department of Medical Oncology, Faculty of Medicine, Karadeniz Technical University, Trabzon, Turkey

<sup>3</sup>Department of Otolaryngology, Faculty of Medicine, Karadeniz Technical University, Trabzon, Turkey

### Abstract

**Objectives:** Adenoid cystic carcinoma (ACC) is a rare tumor that arises from the salivary glands. Since it is rare, there are no consensus recommendations on its treatment strategy. Surgery, radiotherapy (RT), and systemic treatments are options. We aimed to evaluate the treatment outcomes and prognostic factors in ACC.

**Methods:** In this retrospective study; 17 ACC patients were included who were diagnosed with between January 2005 and April 2020 in Karadeniz Technical University Faculty of Medicine. We analyzed the demographic data of these 17 patients, effects of inflammatory markers on overall survival (OS) and progression-free survival (PFS).

**Results:** Ten women and seven men were included in this study. At the diagnosis, 6 patients were metastatic, 5 of them had received chemotherapy. There was no statistical difference in overall survival according to neutrophil/lymphocyte ratio (N/L) and platelet/lymphocyte (T/L) ratio.

**Conclusion:** Primary surgery is the most effective treatment, If possible, metastasectomy should be performed. ACC is a chemotherapy-resistant disease, so chemotherapy should only be given to metastatic, symptomatic, and fit patients. We did not detect the prognostic effect of T/L and N/L in a limited number of ACC samples.

**Keywords:** Adenoid cystic carcinoma, inflammatory markers, salivary gland, treatment

**Cite This Article:** Alandag C, Kazaz SN, Cobanoglu B. Adenoid Cystic Carcinoma; A Single Center 15 Years Experience and Literature Review. EJMI 2021;5(4):491–495.

The salivary gland consists of the acine, ductus, myo-epithelial cells, and basal cells. It produces saliva. There are two groups of salivary glands in the oral cavity: major glands (submandibular, sublingual, parotid) and minor glands. Also, there are many salivary glands in the nasal cavity, paranasal sinuses, pharynx, and larynx. Salivary gland cancers can be of various histologies. Adenoid cystic carcinoma (ACC), mucoepidermoid carcinoma, secretory cell carcinoma, acinic cell carcinoma, and salivary gland ductal carcinoma are the most common histological subtypes. Salivary gland malignant tumors are rarely seen, so

literature on their treatment is based on retrospective or small-scale prospective phase-2 studies.

The main treatment for ACC is surgery by removing the total tumor with a negative surgical margin if the disease is local. If surgery is not feasible initially, it is recommended if it becomes operable after definitive radiotherapy (RT). Salvage surgery (mass excision and neck lymph node dissection) and radiotherapy after salvage surgery are the options for local recurrences if they are not performed before.<sup>[1]</sup> Palliative surgery is recommended in patients with distant metastases if the primary tumor is symptomatic.

**Address for correspondence:** Celal Alandag, MD. Department of Medical Oncology, Sivas Numune Hospital, Sivas, Turkey

**Phone:** +90 506 912 83 19 **E-mail:** dralandag@hotmail.com

**Submitted Date:** October 29, 2021 **Accepted Date:** November 13, 2021 **Available Online Date:** December 29, 2021

©Copyright 2021 by Eurasian Journal of Medicine and Investigation - Available online at [www.ejmi.org](http://www.ejmi.org)

**OPEN ACCESS** This work is licensed under a Creative Commons Attribution-NonCommercial 4.0 International License.



Palliative radiotherapy should be given to inoperable patients.<sup>[2]</sup> Metastasectomy is recommended for solitary lung and liver metastases.<sup>[3]</sup> Radiofrequency ablation or stereotactic radiotherapy can be performed in solitary metastases that are not suitable for surgical metastasectomy. In a study, metastasectomy was performed on 83 patients diagnosed with metastatic ACC, and 5-year survival rates were reported as 84%.<sup>[4]</sup> It is important to determine the treatment indications for metastatic disease. The median overall survival (OS) in metastatic disease is reported as nearly 3 years. Treatment-free follow-up is an option in patients with metastatic disease, especially for asymptomatic patients. Computed tomography or magnetic resonance imaging is recommended every 3-6 months during follow-up. Systemic treatments are recommended for symptomatic, rapidly progressive disease, and visceral crisis. Chemotherapy or targeted therapies are used in systemic therapy. The most important molecular targets are neurotrophic tyrosine receptor kinase (NTRK), Her-2, and androgen receptors. Besides, vascular endothelial growth factor receptor (VEGFR) targeted therapies such as lenvatinib, sorafenib and axitinib have been approved by the FDA.<sup>[5]</sup> Chemotherapy is given in cases that are not suitable for targeted therapy or where these drugs are not available. In patients with good performance, the triple combination of cisplatin, cyclophosphamide, and adriamycin (CAP) is preferred in the first-line metastatic setting. Single-agent vinorelbine, cisplatin, doxorubicin, mitoxantrone, and methotrexate are preferred in patients who are not suitable for combination therapy.<sup>[6]</sup> For ACC, 5 to 10 years overall survival was reported in 74% and 50%, respectively. However, ACC is a disease characterized by multiple recurrences and distant metastases.<sup>[7]</sup> Advanced stage, positive surgical margin, perineural invasion, high grade, high N/L ratios are reported to be associated with poor prognosis.<sup>[8]</sup>

In our study, we aimed to evaluate the efficacy and results of the treatments received by patients diagnosed with ACC in the last 15 years. In addition, we planned to evaluate the effects of inflammatory markers like thrombocyte/lymphocyte (P/L) and neutrophil/lymphocyte (N/L) ratios on treatment results.

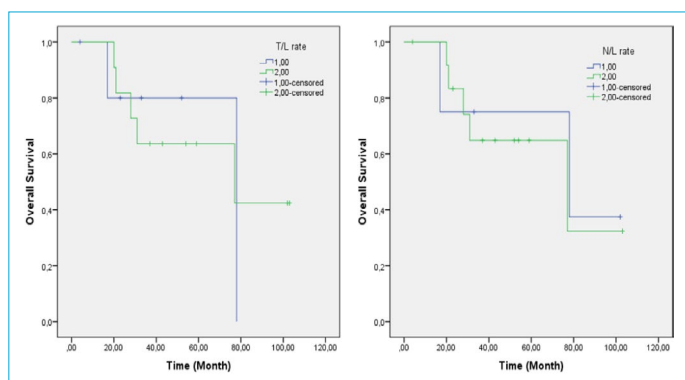
## Methods

In this retrospective study, we conducted patients who were admitted to Karadeniz Technical University Farabi Hospital with the diagnosis of pathologically confirmed ACC, between January 2005 and April 2020. Patients' age at the time of diagnosis, gender, date of diagnosis, histopathological characteristics (primary location of the tumor, surgical margin, tumor diameter, number of metastatic lymph nodes, the diameter of metastasis in positive lymph node,

differentiation, lymphovascular invasion, perineural invasion), and the stage at the time of diagnosis were recorded retrospectively. Response status and duration of response for the primary surgical treatment, adjuvant therapy, and treatments for metastatic disease were recorded. Also, local recurrence, distant metastasis time were noted. The relationship between these parameters and the survival rates in the third and fifth years was investigated. Single and multivariate analyses were performed for survival analysis. T/L and N/L ratios were computed at the time of diagnosis. The relationship of these rates with prognosis, recurrence, and metastasis was investigated. T/L and N/L ratios' cut-off values were taken as 150 and 2, respectively, as stated in the literature.<sup>[8]</sup> We analyzed the overall survival (OS), which was defined as the time elapsed from the date of diagnosis to the date of death from any cause. The follow-up time was defined as the time from the date of diagnosis to the date of death or last follow-up. The statistical analyses were conducted using Statistical Package for Social Sciences (SPSS) version 22 (SPSS Inc, Chicago, IL). Univariate analysis was performed by using the Kaplan–Meier method to estimate the OS of different patient groups, and the groups were compared with the log-rank test. Cox regression analysis was used to determine the association of factors with the OS in the multivariate analysis. In the multivariate analysis, confounders were included if they were significant at a 0.05 level in the univariate analysis (log-rank test) or thought to be important for OS or the effect of the factors. The results were expressed as median OS, median relapse-free survival (RFS), and hazard ratios (HRs) with 95% confidence intervals (CIs). A p-value of <0.05 was considered statistically significant. Ethics committee approval was obtained by the Ethics Committee of Faculty of Medicine, Karadeniz Technical University, on 24.0.2021 with protocol number 2021/32.

## Results

Of the 17 patients diagnosed with ACC included in this study, 10 were women and 7 were men. The median age at diagnosis was 47 (range 21 to 83). All women were diagnosed when they were over 40 years old, 5 of the male patients were diagnosed under the age of 40, three of them were under the age of 25. Seven patients had died and 10 patients were still alive. Five of the seven patients died due to non-cancer reasons. One patient died due to the complication of chemotherapy. Median OS was 77,9 months (95% CI, 29.1-126,7) and median RFS was 64.0 months (95% CI, 35.4-96.4) (Fig. 1). The primary tumor site was the parotid in 5 patients, the nasal cavity in 3 patients, the nasopharynx in 2 patients, the floor of the mouth in 2 patients, the hard palate in 1 patient, the tongue in 1 patient, the submandibular gland in 1 patient, the trachea in 1 patient, and the



**Figure 1.** Overall survival by thrombocyte/lymphocyte (T/L) ratio and overall survival by neutrophil/lymphocyte (N/L) ratio.

lung in 1 patient. At the time of diagnosis 7 patients were stage I, 5 patients were stage II, 2 patients were stage III, and 3 patients were stage IV, according to the 2017 ADCC TNM staging system. The primary treatment of 16 patients was surgical excision and one patient had received radiotherapy. The surgical margin was negative in 7 patients and positive in 10 patients. Local recurrence developed in 5 of 10 patients with positive surgical margins and distant metastasis developed in 4 patients during follow-up. Local recurrence developed in one of the patients with negative surgical margins, and distant metastasis developed in the other. During primary surgery, lymph node dissection was performed in 11 patients, lymph node metastasis was detected in 3 patients. Local recurrence was detected in 2 of

3 patients who were found to have lymph node metastasis at the time of diagnosis, but distant metastasis was not detected in any of them. At the diagnosis, the primary tumor was T1 (<2 cm) in one patient, T2 (between 2-4 cm) in seven patients, T3 (4-6 cm) in six patients, T4 (invasion to the facial nerve) in one patient, and distant metastasis in two patients. Four patients had received adjuvant RT, two patients had received adjuvant chemotherapy. Local recurrence was seen in 7 patients and distant metastasis was seen in 6 patients. The distant metastasis site was lung in 3 patients, bone and lung in 1 patient, lung and liver in 1 patient, and brain in 1 patient. Local recurrence and distant metastasis developed in the patient who received adjuvant paclitaxel/carboplatin but not in the patient receiving cisplatin/docetaxel. Local recurrence developed in 3 of 4 patients who received adjuvant RT, and distant metastasis developed in two. Distant metastasis developed in six patients at the time of diagnosis or during follow-up. Five patients received chemotherapy for metastatic disease. One patient (with bone and liver metastases) received 5 cycles of cisplatin/adriamycin and a partial response was achieved, two patients with lung metastases had a stable response to 3 cycles of cisplatin/doxorubicin, one patient received 3 cycles of paclitaxel/carboplatin, but the patient died without response evaluation. Two patients had given cyclophosphamide, adriamycin, cisplatin and achieved stable disease (Table 1). Metastectomy was performed in two patients, one with a mass in the brain, and lung in another. No tar-

**Table 1.** Distribution of the patients of the series according to age, sex, tumor site, treatment, and response to treatment.

Age/Sex	Primary location	Primary treatment	Surgical margin	Adjuvant	Local recurrens	Metastasis	Regimen	Response	Exitus
74, F	Tongue	Surgery	+	No	Yes	No			Yes
47, F	Lung	Surgery	+	No	No	No			No
76, F	Nasofarinx	Surgery	+	No	Yes	No			Yes
24, M	Nasal cavity	Surgery	+	No	Yes	No			No
73, F	Nasal cavity	Surgery	+	No	Yes	Lung	PC	Toxicity related ex	Yes
47, F	Parotid	Surgery	-	CT (PC)	No	No			No
81, M	Hard palate	Surgery	+	RT	No	No			Yes
20, M	Nasopharynx	Surgery	-	RT	Yes	No			No
50, F	Parotid	Surgery	-	No	No	No			No
83, M	Parotid	Surgery	+	No	No	No			Yes
23, M	Parotid	Surgery	-	No	No	No			No
31, M	Trachea	Surgery	+	No	No	No			No
43, F	Nasal cavity	Surgery	+	CT (Cisplatin/Docetaxel)	No	Lung-bone	AP	Partial response	Yes
40, F	Oral cavity	CT	-	No	No	Lung-Liver	CAP	Stable	No
37, M	Parotid	Surgery	+	RT	Yes	Lung	Cispaltin-docetaxel	Stable	No
80, F	Maxillary sinus	Surgery	+	RT	Yes	Brain			Yes
60, F	Oral cavity	Surgery	+	No	No	Lung	CAP	Stable	No

AP: Adriamycin/Cisplatin; CP: Cyclophosphamide/Adriamycin/Cispaltin; PC: Pactitaxel/Carcoplatin.

geted therapy was used in any of the patients, they were not included in the clinical study, and the next-generation sequencing test was not performed. The N/L ratio and T/L ratio at the time of diagnosis were measured. No statistical difference was found in terms of OS between those with N/L ratio  $<2$  and  $\geq 2$ , also T/L ratio  $<150$  and  $\geq 150$  ( $p=0.37$ ). Also, there wasn't a statistical difference in terms of recurrence for the N/L ratio ( $p=0.76$ ) and T/L ratio ( $p=0.67$ ). One of seven patients with negative surgical margins, 6 of 10 patients with positive surgical margins had died. There was no significant difference between surgical margin positive and negative patients in terms of OS ( $p=0.42$ ).

## Conclusion

Adenoid cystic carcinoma is rare cancer, so information in the literature is limited. There is no definitive consensus regarding treatment approaches, especially in metastatic disease. In this respect, some treatment decisions are made by referring to case reports, case series, and retrospective publications in the literature. We collected the last 15 years' cases in our center. There were 1676 head and neck cancers, consistent with the literature, approximately 1% of head and neck cancers admitted to our hospital were ACC. In our study, 58% of the patients (10 patients) were female, it is noteworthy that women were diagnosed at an older age but men at an earlier age. There is conflicting data in the literature regarding the distribution of age and gender for ACC, although it is generally reported that it is more common in the elderly, it can be seen in young adults, children, and adolescents. In a series of 74 patients, the rate of female patients was found to be 48%. In our study, the most common primary site of the tumor was the minor salivary glands (60%), followed by the parotid glands (29%). In a study, it is reported that the primary site of head and neck ACCs originates from the minor salivary gland at a rate of 50-60% and parotid at a rate of 25%.<sup>[9]</sup> Patients' rate of whom were at the metastatic stage at the time of diagnosis was 11% and the most common metastasis site was the lung. Similarly, in the literature, lungs are reported to be the most common metastasis site with a rate of 30%.<sup>[6]</sup> Surgical margin (SM) positivity was seen to be important in terms of local recurrence and distant metastasis. It was remarkable that 6 of 7 patients with negative SMs were still alive and 6 of 10 patients with positive SMs died. In our study, neck dissection was performed in 3 patients and lymph node metastasis was found in all of them. None of the three patients had distant metastases but two had local recurrence. In a study, involving 507 ACC patients, the SM was negative in 57% of the patients, neck dissection was performed in 52% of the patients, nodal metastasis was found in 38%, the 5-year survival rate of those with positive SM was 79%,

and those with negative SM were 63%. It was stated that lymph node metastasis is a poor prognostic factor for 5-year OS and DFS.<sup>[10]</sup> In our study, 2 patients died due to ACC and 5 patients died due to other reasons. This was attributed to the high rate of comorbidity, as the patients were of advanced age at the time of diagnosis. While the 5-year survival rate was 74% in our study, 5-year survival was 63% in one series and 90 % in another series.<sup>[1,11]</sup> In a study, oral cavity and paranasal sinus tumors were found to have a worse prognosis (in terms of OS and DFS) than major salivary gland tumors.<sup>[10]</sup> In our study, N/L and T/L ratios were not found to be significant in terms of recurrence, but it is reported in the literature that the N/L ratio predicts recurrence for sinonasal cancers.<sup>[12]</sup> Two of our patients who developed metastases had been given cisplatin/docetaxel and one had stable disease for 13 months, while the other patient died one month after the last cycle of chemotherapy despite a partial response. Two of our patients received the CAP regimen, a stable response was obtained and no grade 3/4 side effects had developed. In one study, it is reported that 68% stable and partial response was observed with CAP treatment (8 of 12 patients), and it is emphasized CAP regimen can be given as cytotoxic therapy for fit patients, and cisplatin/5-FU, single-agent vinorelbine or mitoxantrone are other options in patients who cannot tolerate triple regimen.<sup>[13]</sup>

There was no study about this issue in the Black Sea Region, before. The low number of patients was one of the most important handicaps of this study. Because of the rareness of this histology, also there were limited data in the literature. Treatment indications and choice of treatment regimens are not included in current guidelines about ACC. We think this study may give hints to future studies from our region.

## Disclosures

**Ethics Committee Approval:** Ethics committee approval was obtained by the Ethics Committee of Faculty of Medicine, Karadeniz Technical University, on 24.0.2021 with protocol number 2021/32.

**Peer-review:** Externally peer-reviewed.

**Conflict of Interest:** None declared.

**Authorship Contributions:** Concept – C.A.; Design – C.A.; Supervision – S.N.K.; Materials – B.C.; Data collection &/or processing – C.A.; Analysis and/or interpretation – S.N.K.; Literature search – S.N.K.; Writing – C.A.; Critical review – S.N.K.

## References

1. Ellington CL, Goodman M, Kono SA, Grist W, Wadsworth T, Chen AY, et al. Adenoid cystic carcinoma of the head and neck: Incidence and survival trends based on 1973-2007 surveillance, epidemiology, and end results data. *Cancer* 2012;118:4444-51.

2. Demircan V, Akmansu M, Aydil U, Türkcan A, Au D, Sayar E. Single institutional experience of head and neck adenoid cystic carcinomas. *Otorhinolaryngol Head Neck Surg* 2018;3:2–4.
3. Park I, Lim SN, Dok HY, Park H, Sun B, Pil HL, et al. Metastasectomy for hepatic metastases from adenoid cystic carcinoma of the trachea. *Gut Liver* 2009;3:127–9.
4. Liu D, Labow DM, Dang N, Martini N, Bains M, Burt M, et al. Pulmonary metastasectomy for head and neck cancers. *Ann Surg Oncol* 1999;6:572–8.
5. Mimica X, McGill M, Hay A, Karassawa Zononi D, Shah JP, Wong RJ, et al. Distant metastasis of salivary gland cancer: Incidence, management, and outcomes. *Cancer* 2020;126:2153–62.
6. Laurie SA, Ho AL, Fury MG, Sherman E, Pfister DG. Systemic therapy in the management of metastatic or locally recurrent adenoid cystic carcinoma of the salivary glands: a systematic review. *Lancet Oncol* 2011;12:815–24.
7. Mannelli G, Cecconi L, Fasolati M, Santoro R, Franchi A, Gallo O. Parotid adenoid cystic carcinoma: Retrospective single institute analysis. *Am J Otolaryngol* 2017;38:394–400.
8. Brkic FF, Kadletz L, Jank B, Cede J, Seemann R, Schneider S, et al. Pretreatment assessment of hematologic and inflammatory markers in adenoid cystic carcinoma: neutrophil/lymphocyte ratio is associated with multiple recurrences. *Oral Surg Oral Med Oral Pathol Oral Radiol* 2019;127:408–16.
9. Kokemueller H, Eckardt A, Brachvogel P, Hausamen JE. Adenoid cystic carcinoma of the head and neck - A 20 years experience. *Int J Oral Maxillofac Surg* 2004;33:25–31.
10. Amit M, Na'ara S, Trejo-Leider L, Ramer N, Burstein D, Yue M, et al. Defining the surgical margins of adenoid cystic carcinoma and their impact on outcome: An international collaborative study. *Head Neck* 2017;39:1008–14.
11. Tirelli G, Capriotti V, Sartori G, Tofanelli M, Marcuzzo AV. Primary adenoid cystic carcinoma of the frontal sinus: case description of a previously unreported entity and literature review. *Ear Nose Throat J* 2019;98:E8–12.
12. Turri-Zononi M, Salzano G, Lambertoni A, Giovannardi M, Karligkiotis A, Battaglia P, et al. Prognostic value of pretreatment peripheral blood markers in paranasal sinus cancer: Neutrophil-to-lymphocyte and platelet-to-lymphocyte ratio. *Head Neck* 2017;39:730–6.
13. Chae YK, Chung SY, Davis AA, Carneiro BA, Chandra S, Kaplan J, et al. Adenoid cystic carcinoma: Current therapy and potential therapeutic advances based on genomic profiling. *Oncotarget* 2015;6:37117–34.